

**The Management of Middle Ear Disease:**

**“Best Practice” Guidelines**  
**for**  
**Providers in Aboriginal Health Care Settings**

Revised Edition  
May 2003

J.A. Hildes Northern Medical Unit  
Department of Community Health Sciences  
Faculty of Medicine  
University of Manitoba



UNIVERSITY  
OF MANITOBA



# THE MANAGEMENT OF MIDDLE EAR DISEASE: “BEST PRACTICE” GUIDELINES FOR PROVIDERS IN ABORIGINAL HEALTH CARE SETTINGS

## INTRODUCTION TO REVISED EDITION, APRIL 2003.

The first iteration of guidelines for the management of ear disease in the aboriginal health care programs of the J.A. Hildes Northern Medical Unit was presented at the Tenth International Congress on Circumpolar Health in 1996. This revised edition is a consensus document that reflects current “best practice” approaches as recommended by clinicians of the J. A. Hildes Northern Medical Unit, including primary care practitioners, audiology, otolaryngology, paediatrics and paediatric infectious disease.

Middle ear disease and associated hearing loss continues as a significant burden for the children of the Kivalliq Region of Nunavut. Primary health care providers continue to be challenged to provide consistent care for acute and chronic ear disease and to apply appropriate criteria for referral. These best practice guidelines reflect realistic and achievable standards of care for community settings, and address areas of controversy.

### ***What is new?***

- Second-line antibiotic therapy recommendations for acute otitis media have been revised to reflect changing patterns of bacterial resistance.
- Antibiotic prophylaxis is no longer recommended for the management of otitis media with effusion and recurrent acute otitis media. This reflects increased concern regarding bacterial resistance.
- The management of chronic otitis media with a perforation remains conservative, with emphasis on aural toilet and local care. The use of topical antibiotic or antibiotic-steroid ear drops are no longer routinely recommended

## **ACUTE OTITIS MEDIA (AOM)**

Acute otitis media (AOM) can be defined as pus in the middle ear accompanied by signs or symptoms of ear infection (including pain, fever, irritability, loss of appetite; and tympanic membrane erythema, bulging, or acute perforation with drainage of purulent material). Amoxicillin continues to be the appropriate first-line therapy for acute otitis media (AOM). It is inexpensive and continues to be highly effective in standard dosages. Patterns of *S. pneumoniae* (pneumococcus) antibiotic resistance do not dictate the need for alternative first-line therapy. For children who are allergic to penicillin, therapy can be selected from azithromycin, trimethoprim-sulfamethoxazole, or

a combination of erythromycin and sulfisoxazole. The duration of therapy is recommended as ten days, with the exception of azithromycin for which therapy should be five days.

There should be improvement in symptoms within 48-72 hours if there has been compliance with antibiotic therapy. If treatment fails after 72 hours, a second-line therapy is indicated, based upon the premise that the infection may be caused by a resistant organism. Therapy can be selected from either high dose amoxicillin (90-100 mg/kg/24h) or adding amoxicillin/clavulanate to the already initiated amoxicillin; these second-line regimens should be continued for seven days, thereby resulting in approximately ten days of antibiotic therapy. The community physician or paediatrician should be consulted for treatment failures in the penicillin allergic patient. If there is continued treatment failure despite second-line therapy, the community physician or paediatrician should be contacted.

Acetaminophen or ibuprofen may be useful for pain relief and fever control. Eardrops containing anaesthetic (Auralgan™) may provide effective short-term pain relief. This should not be used in the presence of a perforation of the tympanic membrane.

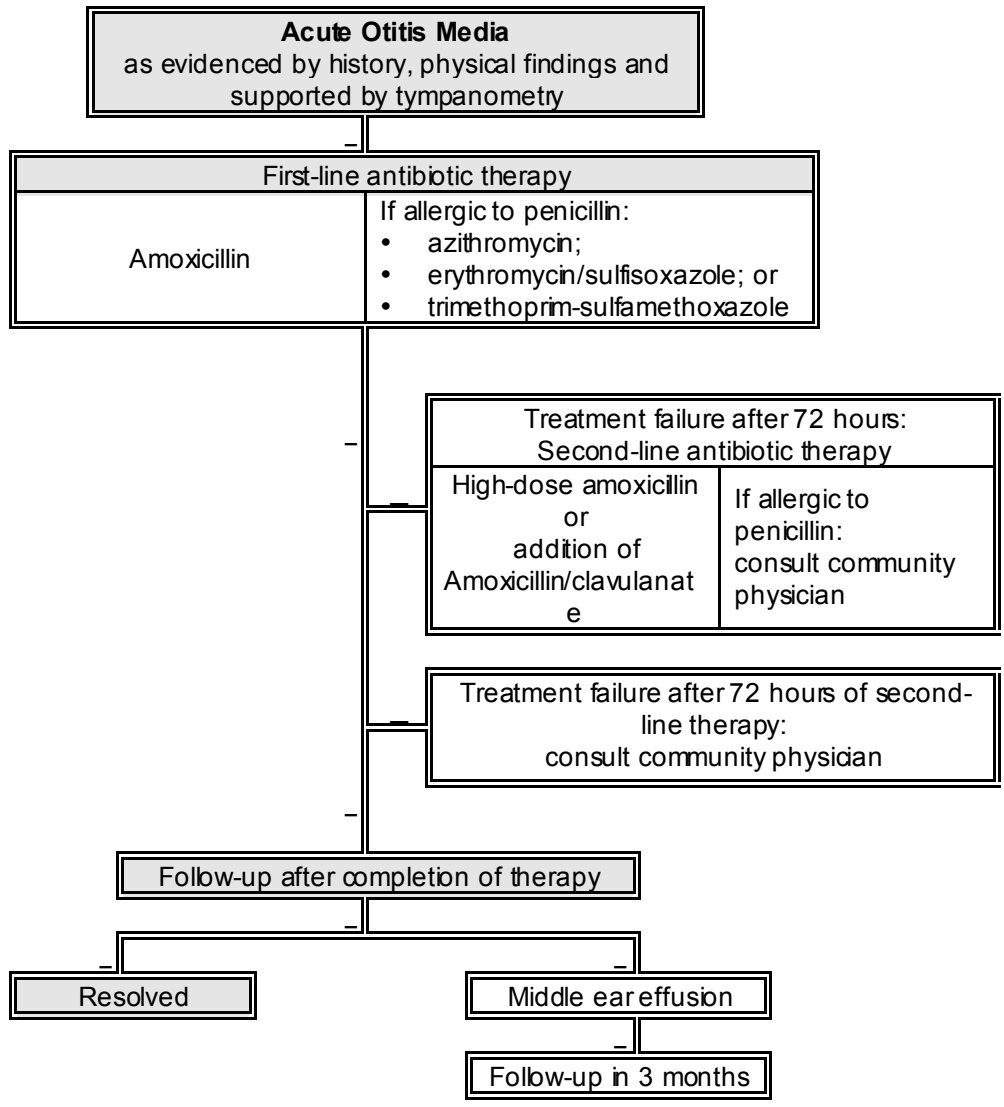
Second-line therapy can be justified if the patient has AOM and has been treated with first-line therapy in the preceding month.

AOM may be associated with acute tympanic membrane perforation. This may be evidenced by purulent or blood stained discharge, and is often associated with resolution of pain. Acute tympanic membrane perforation, of itself, is not an indication for a change in therapy.

All children should be assessed after completion of the ten day course of therapy. Assessment should include tympanometry for detection of middle ear effusion.

### ***At issue:***

The management of AOM in any infant three months of age or younger, should be discussed with a physician. Management of AOM without antibiotics has been reported in the medical literature, but has not been studied in the target population of this document. This approach should only be considered in children aged two years or older, who do not have severe pain or significant bulging of the tympanic membrane, and who can be monitored; antibiotics should be prescribed if symptoms persist after 72 hours. Duration of therapy is discussed in the medical literature and a shorter course of therapy has been effective in some circumstances; this approach is not advocated as no studies have been conducted in the target population of this document. Antihistamines, decongestants, prednisone and products advertised as cough and cold remedies for children are not indicated in the treatment of AOM.



<b>Antibiotic Dosage Guide</b>	
Amoxicillin	40-50 mg/kg/24h divided tid for 10 days
Amoxicillin, high dose	90-100 mg/kg/24h divided tid
Amoxicillin/clavulanate	Based on amoxicillin dosage 40-50 mg/kg/24h divided tid
Azithromycin	10 mg/kg given od on day 1, then 5 mg/kg od for the next 4 days
Erythromycin/sulfisoxazole (1:3)	Based on erythromycin 40 mg/kg/24hr divided qid for 10 days
Trimethoprim-sulfamethoxazole	8 mg/kg TMP and 40 mg/kg SMX/24hr divided bid for 10 days
Reference: Pediatric Drug Dosage Handbook. 8 <sup>th</sup> Edition	

## **RECURRENT ACUTE OTITIS MEDIA**

Recurrent acute otitis media is defined as three or more separate episodes of AOM in six months, or four or more episodes within one year. Subsequent episodes should be managed as indicated above for AOM. The child should be referred to the community physician to consider referral to audiology and otolaryngology. Modifiable risk factors including exposure to environmental tobacco smoke should be addressed. Consideration should be given to pneumococcal (Prevnar™) and influenza vaccine if not already received.

### ***At issue:***

Antibiotic prophylaxis is no longer recommended due to increasing concerns of bacterial resistance, and little evidence of efficacy. Topical or systemic decongestants and antihistamines play no role in the prevention of recurrent episodes of AOM. The laboratory assessment for host defence mechanisms is unnecessary for children with recurrent AOM, unless there are other significant indicators of impaired immune status.

## **OTITIS MEDIA WITH EFFUSION (OME)**

Otitis media with effusion (OME) can be defined as fluid in the middle ear without signs or symptoms of ear infection. OME may follow acute otitis media, accompany an acute upper respiratory infection, or may be an incidental finding. The majority of effusions resolve spontaneously within three months of onset. There may be an associated hearing loss, but the presence of MEE may go unnoticed by parent and child. Tympanometry may assist in diagnosis and in the objective assessment of the course of an effusion.

If OME persists after three months, the child should be referred for hearing evaluation. If there is bilateral hearing deficiency, defined as a 20-decibel hearing threshold level or worse in the better-hearing ear, referral should be made to otolaryngology as bilateral myringotomy with pressure equalization tube insertion may be a treatment option.

Consideration should be given to pneumococcal (Prevnar™) and influenza vaccine if not already received.

Environmental risk factors include exposure to tobacco smoke; parents should be advised of the benefits of decreasing children's exposure to tobacco smoke.

### ***At issue:***

Most cases of OME resolve spontaneously. The use of antibiotic therapy is not currently recommended as there is little benefit, and there are increasing concerns

regarding bacterial resistance. There is no evidence that antihistamines or decongestants used separately or together, have any effect on OME. Steroids are not recommended as there is little evidence of benefit, and adverse effects are not insignificant. Adenoidectomy is not recommended as there is little scientific evidence of benefit and potential harm includes the risks of general anesthesia and the possibility of excessive postoperative bleeding. Tonsillectomy, either alone or with adenoidectomy, has not been found effective for OME. If there is a history or clinical finding of tonsillar or adenoid hypertrophy, myringotomy with pressure equalization tube insertion plus adenoidectomy or tonsillectomy and adenoidectomy may be a treatment option.

Environmental risk factors for OME include bottle-feeding rather than breast-feeding, but this risk factor is rarely modifiable by the time the diagnosis is established. Group child-care facility attendance is associated with a slightly higher risk of getting OME, but research does not show benefit from removing the child from the group child-care facility.

## **CHRONIC TYMPANIC MEMBRANE PERFORATION**

Chronic tympanic membrane perforation can be defined as the presence of perforation for greater than three months. It is most often the result of recurrent AOM. It may or may not be accompanied by purulent drainage. The goal of treatment is directed towards spontaneous healing of the perforation.

Drainage associated with chronic tympanic membrane perforation is ordinarily the result of contamination; *pseudomonas aeruginosa* is the most common pathogen. The focus of treatment is intensive aural cleansing to achieve a clean, dry and acidified external and middle ear. Acetic acid is a useful anti-infective as *pseudomonas* cannot thrive in an acidic environment. The ear canal must be debrided by swabbing with a cotton-tipped applicator under direct vision, and without entering the middle ear. The ear canal can then be irrigated gently with a syringe using 1% acetic acid. A parent should be instructed to continue therapy with swabbing of the ear canal and instillation of 1% acetic acid by dropper. This can be continued up to three times daily until the discharge resolves. Cotton balls should not be used to occlude the ear canal when there is discharge.

Once the discharge has ceased, protection from contamination is important. Ear plugs should be worn while showering, bathing, or swimming. Cotton balls coated with petroleum jelly are an effective alternative to ear plugs. Recurrence of drainage in the presence of continued perforation should be treated with intensive aural cleansing and acetic acid, as noted above. If there are associated purulent upper airway secretions, consideration could be made to the addition of an oral antibiotic.

A community physician should be consulted if chronic tympanic membrane perforation is associated with pain, fever, bloody discharge, or failed response to treatment.

Children with tympanic membrane perforation should be referred for hearing evaluation. Hearing loss defined as a 20-decibel hearing threshold level or worse in the better-hearing ear should be addressed by individual hearing aids, classroom soundfield systems, or preferred seating arrangements in classroom settings where there are no soundfield systems.

Referral to otolaryngology should be considered if there is a conductive hearing loss. Ordinarily, tympanoplasty is considered with a goal of improving hearing only if the patient is at least twelve years of age, if the perforation has been present for two years, and if there has been no associated discharge for a minimum of six months.

***At issue:***

Otological antibiotic or antibiotic/steroid drops are no longer recommended. Ototoxicity has been definitively associated with gentamycin preparations if there is a tympanic membrane perforation. Systemic antibiotic therapy for CSOM is not recommended. Culture of fluid from the ear canal is not indicated as results do not reflect middle ear pathogens, and will not influence therapy. Similarly, nasopharyngeal culture is not indicated as there is no correlation with the bacterial pathogens of the middle ear.

**SUMMARY**

'Best practice' guidelines for the management of middle ear disease in children of the Kivalliq Region of Nunavut have been established by consensus. The guidelines will facilitate accepted approaches by primary health care providers, and allow for consistent education of the child and parent regarding the plan of management.

**ACKNOWLEDGEMENTS**

The following individuals were members of the working group for this document: Dr. L. DuVal, Otolaryngology; Dr. J. Embree, Infectious Disease; Dr. A. Macaulay, Coordinator, Inuit Health Program, J. A. Hildes Northern Medical Unit; Dr. B. Martin (Chair), Director, J. A. Hildes Northern Medical Unit; Ms. Heather Schilling, Audiology.

**CORRESPONDENCE**

J. A. Hildes Northern Medical Unit  
University of Manitoba  
T162-770 Bannatyne Avenue  
Winnipeg, Manitoba, Canada, R3E 0W3

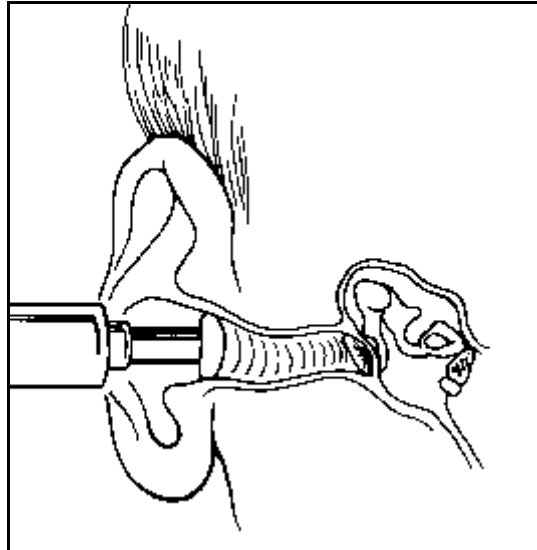


## ADDENDUM 1. TYMPANOMETRY

Tympanometry is a simple, non-invasive test that maybe useful:

(1) in identifying Eustachian tube obstruction with concomitant negative middle-ear pressure or otitis media; (2) in identifying tympanic membrane perforations or patent pressure-equalization tubes; and (3) to some extent, in the differential diagnosis of middle-ear disease.

An appropriately sized soft ear piece is fitted to the probe tip and a seal is obtained at the opening of the ear canal. A tone is transmitted through the probe. Movement of the tympanic membrane in response to the tone is measured while the air pressure in the external canal is varied. A tympanogram is a graphic display of the results.



Adapted from: Pfenninger: Procedures for Primary Care Physicians, 1st ed., Copyright © 1994 Mosby-Year Book, Inc.

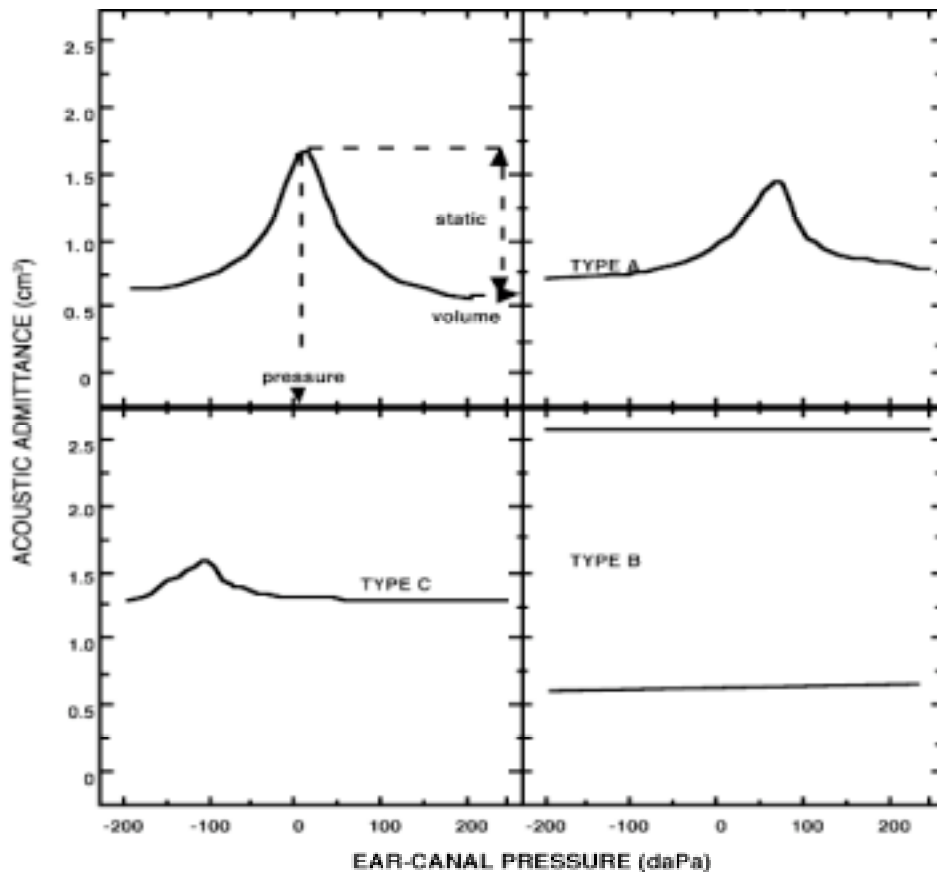
The tympanogram should be analyzed with respect to pressure, ear canal volume, and peak static acoustic admittance (compliance peak). A normative box is ordinarily displayed to assist the operator in identifying test results that fall outside the normal range.

**Middle ear pressure:** normal range -150 to +100 daPa. Middle ear effusion will be associated with negative middle ear pressure which cannot be adjusted due to associated eustachian tube dysfunction. Positive pressure peaks may be noted in the early stages of acute otitis media. Absent pressure peaks occur in the presence of a perforated tympanic membrane, or with patent pressure equalization tubes.

**Ear canal volume (E.C.V.):** normal values 0.2 - 2.5 cm<sup>3</sup> (values in Inuit are higher than other populations). An increased measurement can indicate an open perforation or patent pressure equalization tube, and a smaller volume may indicate an ear canal obstruction.

**Compliance peak:** normal values 0.2 - 1.4 cm<sup>3</sup>. Above normal amplitude is indicative of partial scarring of the tympanic membrane or healed perforations. Below normal amplitude may be attributed to middle ear fluid or severe eardrum scarring which restricts the mobility of the tympanic membrane.

A popular method of categorizing tympanometric shapes is identified in the accompanying diagram. A normal tympanogram is referred to as **Type A**, with compliance peak at 0 daPa. If the Eustachian tube is obstructed, then a negative middle-ear pressure will result and the tympanogram will peak at a similar negative pressure; the resulting **Type C** tympanogram is shown. As the middle-ear cavity fills with fluid, eardrum movement is restricted, resulting in a flat **Type B** tympanogram as shown in the lower tracing. Flat tympanograms are also recorded with patent PET and eardrum perforations as shown in the upper tracing. A tympanometric volume measurement can help to differentiate between an intact and an abnormal tympanic membrane. A tympanometric volume in excess of 1.0 cm<sup>3</sup> in small children and 2.5 cm<sup>3</sup> in adult males may be consistent with a perforation of the eardrum.



Modified from: The Audiology Primer for Students and Health Care Professionals. James H. Quillen  
VA Medical Center.

## ADDENDUM 2. HEARING LOSS

