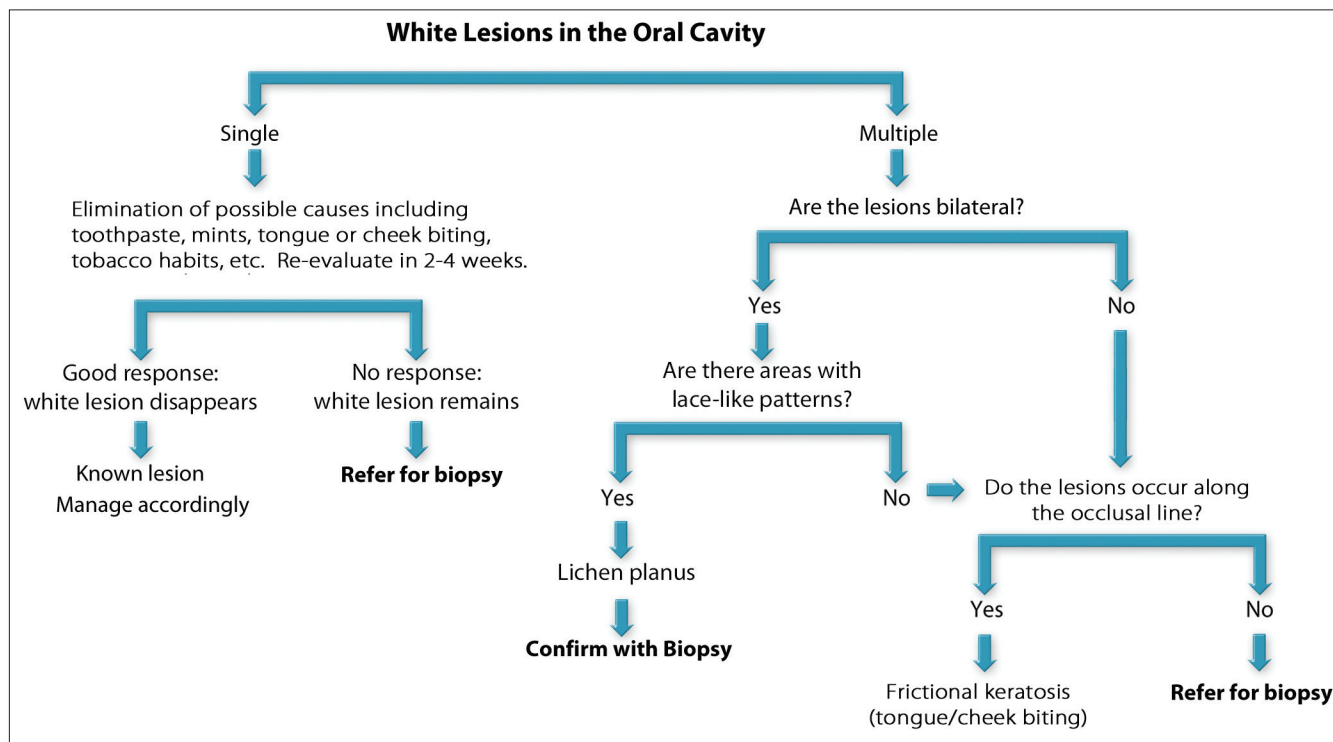


# Differential Diagnosis of White Lesions of the Oral Cavity

The differential diagnosis of lesions or abnormalities of the oral cavity will help non-dental healthcare providers (HCPs) to refer at-risk patients to the appropriate provider so they can be re-examined more closely.



Multiple white lesions that do not rub off should be noted in patient records, including the location of the lesions. Oral lichen planus is usually bilateral on both the buccal mucosa and/or the lateral borders of the tongue. A lace-like pattern is typical of lichen planus and the patient should be referred for a confirmatory biopsy. Frictional keratosis can occur both as a single white lesion and as multiple lesions along the occlusal line. Some patients will bite their right lateral tongue and right cheek, or the lower lip and the cheek. Again, patient observation may reveal the source of the keratoses. However, if no specific etiology is found for the presence of the white lesions, the patient should be referred for a biopsy.

Potential referrals could include the patient's dentist, an oral surgeon, oral pathologist or, in cases of suspected oropharyngeal cancer, an otolaryngologist. The use of a referral form that documents the location and clinical presentation of suspected lesions, and the patient's risk profile, is an excellent tool for assisting non-dental HCPs in documenting important information that should be communicated to the doctor of referral. It is also very important for physicians to enter this information in patients' medical records, and to develop a system that ensures follow-up on patients who are referred for suspicious lesions. Physicians should also re-examine the site of specific precancerous lesions in at-risk patients who were not referred.

**A referral form designed to specifically detail this information is included as one of the collateral materials for this course and can be downloaded at [www.oralhealthed.com](http://www.oralhealthed.com).**

Evaluate the mouth to see if the white lesion is single or multiple. If it is single, look for local sources of irritation, such as cheek, tongue or lip biting. White lesions caused by biting generally occur along the occlusal line. Often, the patient is unaware of the habit, so by observing the patient during the examination you can often witness the biting. Ask the patient if he/she habitually uses mints or chewing gum and if new toothpaste or mouthwash has been used recently. Ask about the use of tobacco products as well. Smokeless tobacco can cause a white area in the location where the tobacco is placed.

If you suspect that one of these agents could be causative, ask the patient to discontinue the suspected cause(s), and

re-evaluate the oral tissue in two weeks. If the lesion resolves, then no further management is needed. However, if the lesion remains, the patient needs to be referred for biopsy. Cigarette smokers may have an area of leukoplakia on the ventral tongue and the floor of the mouth. Although these lesions may be reversible if the patient stops smoking, he/she should be initially referred for a biopsy, since these two oral sites are at high risk for cancer.

White lesions in the mouth (whether single or multiple) that can be rubbed off are compatible with oral candidiasis. Appropriate treatment with antifungal medication or referral to a specialist for treatment is indicated.