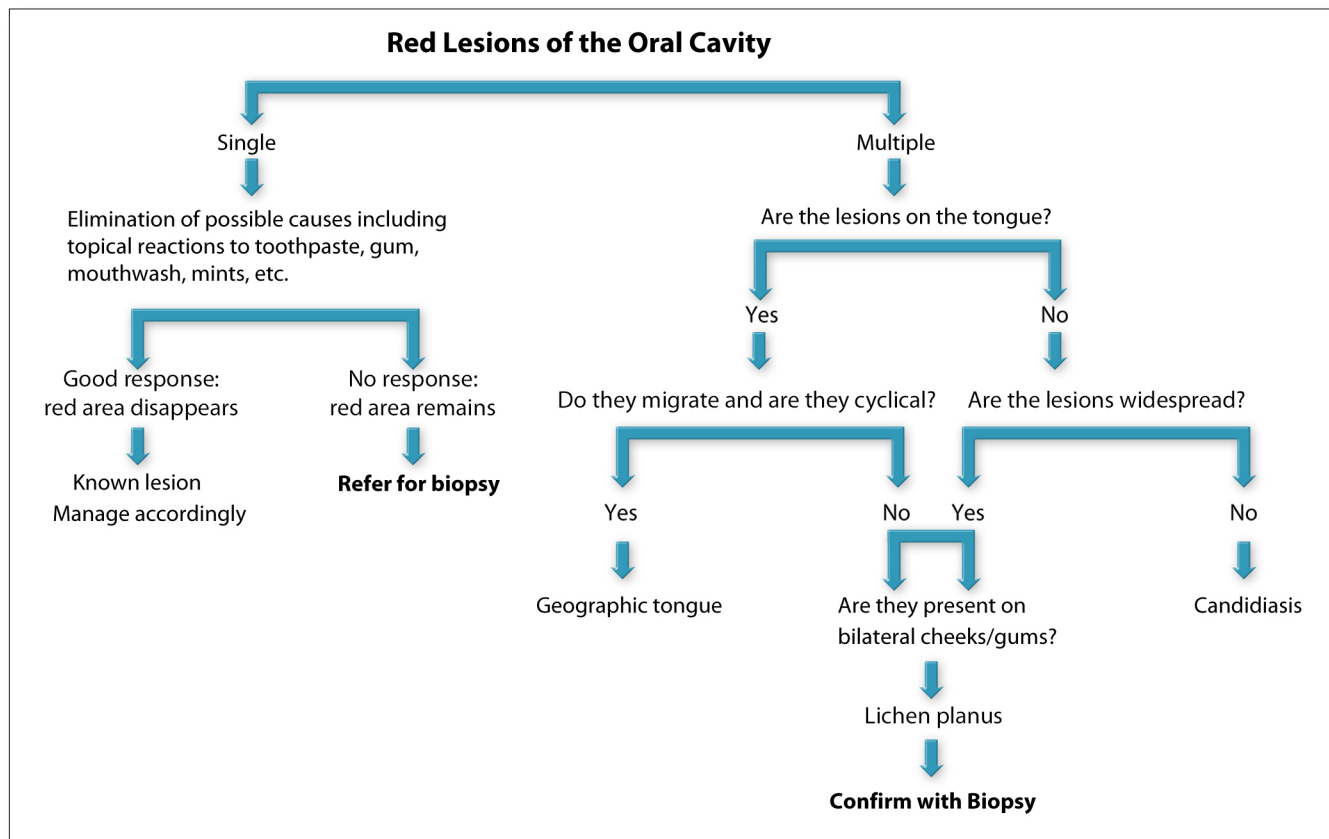


# Differential Diagnosis of Red Lesions of the Oral Cavity

The differential diagnosis of lesions or abnormalities of the oral cavity will help non-dental healthcare providers (HCPs) to refer at-risk patients to the appropriate provider so they can be re-examined more closely.



Examine the mouth to see if the red lesion is single or multiple. If it is single, look for local sources of irritation, such as a poorly fitting denture or a broken tooth. Ask the patient if he/she recalls biting the area accidentally, or if he/she habitually uses mints. Inquire if new toothpaste, mouthwash or chewing gum has been used prior to the onset of the red area. If you suspect that one of these possibilities could be causative, then ask the patient to discontinue the suspected cause(s) and re-evaluate the area in two weeks. If the red area remains, then the patient needs to be referred for biopsy.

If the red lesions in the mouth are multiple, make a note of the location. If the lesions are primarily on the dorsal tongue and the patient states that the lesions move around and come and go, this is consistent with geographic tongue, a benign condition. If the lesions do not migrate and are also seen on the buccal mucosa and gums, this clinical presentation is consistent with lichen planus and the patient should be referred for a confirmatory biopsy. If the red lesion is on the midline of the dorsum of the tongue and not cyclical or noted elsewhere, then the diagnostic consideration is median rhomboid glossitis, a type of oral candidiasis that has a unique clinical appearance. Appropriate treatment with antifungal medication such as clotrimazole will usually resolve the red area. Oral candidiasis can also present as multiple red areas throughout the oral cavity. In denture wearers, especially 24-hour wearers, the tissue under the denture can appear very red; this form of candidiasis is called erythematous candidiasis.

**A referral form designed to specifically detail this information is included as one of the collateral materials for this course and can be downloaded at [www.oralhealthed.com](http://www.oralhealthed.com).**