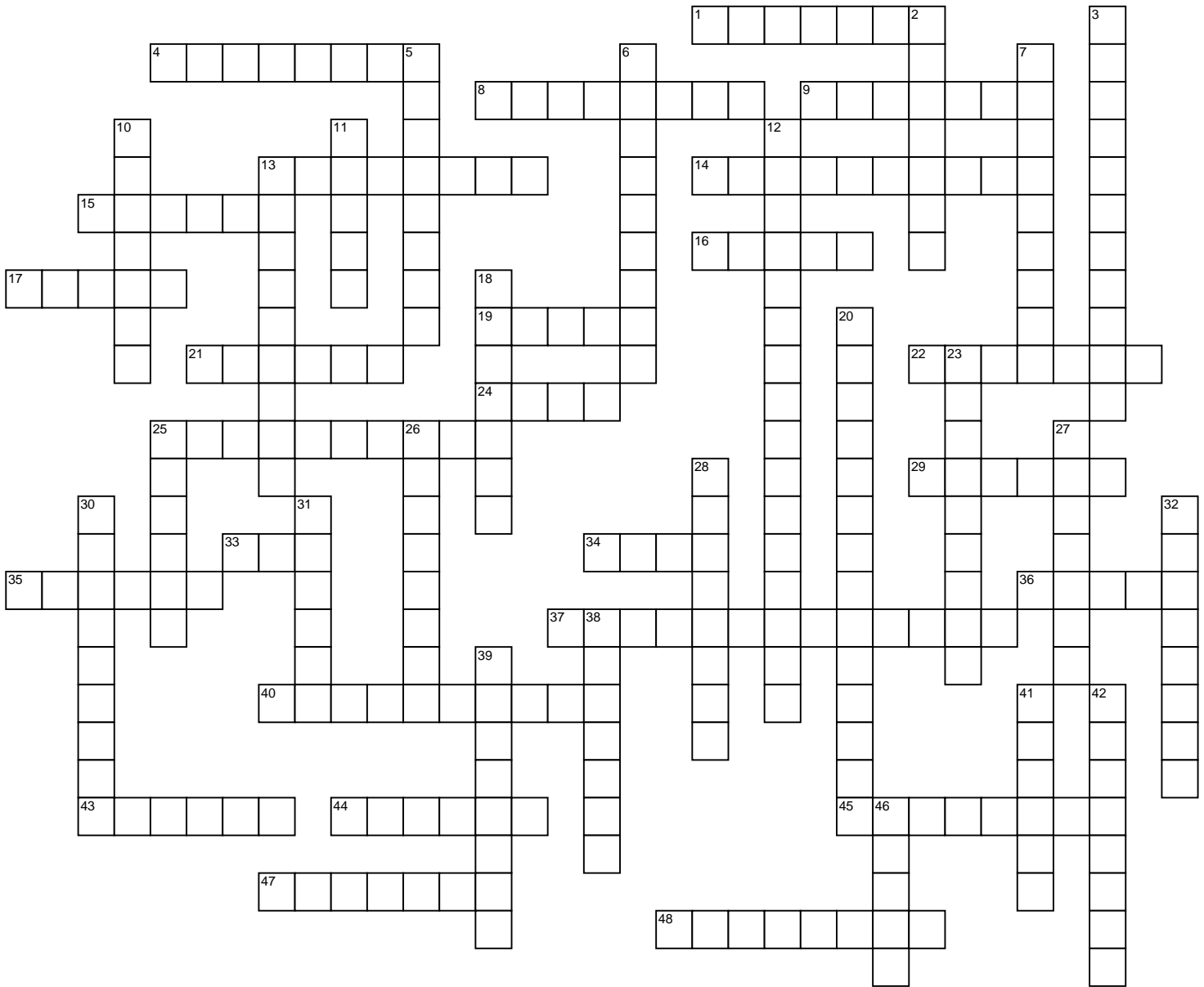


# Nervous System 1



Dr. J.E. Bruni B.Sc., M.Sc., Ph.D., University of Manitoba

- |  |   |  |   |
|--|---|--|---|
| <p><b>ACROSS</b></p> <p>1 Veins that drain the skull</p> <p>4 Effective in reducing symptoms of a hypokinetic dyskinesia</p> <p>8 Discoverer of speech comprehension center</p> <p>9 Loss of taste</p> <p>13 Inability to recognize/produce emotional emphasis in speech</p> <p>14 Common disorder of cranial nerve VII (2 wds.)</p> <p>15 Junction of occipital and sphenoid bones</p> <p>16 10th cranial nerve</p> <p>17 Cerebellar equivalent of gyri</p> <p>19 Discoverer of "black reaction"</p> <p>21 Midbrain roof</p> <p>22 Loss of smell</p> <p>24 Ganglion housing nerve cells innervating the parotid gland</p> | <p>25 CSF filled brain cavities</p> <p>29 Result of denervation of dilator pupillae muscle</p> <p>33 Membrane adherent to brain surface</p> <p>34 "Knee" of the internal capsule</p> <p>35 Efferent fiber bundle of the hippocampus</p> <p>36 Accompanying Nobel laureate of Golgi (1906)</p> <p>37 Also known as globus pallidus</p> <p>40 Nerve innervating TMJ</p> <p>43 Cause of cerebral ischemia</p> <p>44 Incoordination of movement</p> <p>45 Potential space between the the dura and arachnoid</p> <p>47 Brain stem source of olivocerebellar fibers</p> <p><b>DOWN</b></p> | <p>2 Recently evolved nucleus of corpus striatum</p> <p>3 Pia + arachnoid</p> <p>5 Veins that traverse the skull</p> <p>6 Rhombencephalon</p> <p>7 Specialized ependymal cells</p> <p>10 Cerebral cortex</p> <p>11 Famous for "le grand lobe limbique"</p> <p>12 Cells introduced by Del Rio Hortega</p> <p>13 Star-shaped neuroglial cell</p> <p>18 Inability to appreciate significance of sensory stimuli</p> <p>20 Fiber content of white rami communicantes</p> <p>23 Feature of vestibulo-ocular reflex</p> <p>25 "Worm-like" division of cerebellum</p> <p>26 Name given to tracts of secondary sensory fibers in the brain stem</p> <p>27 Ganglion housing nerve cells innervating the ciliary muscle</p> <p>28 Feltwork of neuronal processes</p> | <p>30 Loss of muscle function</p> <p>31 Craniometric site of posterior fontanelle</p> <p>32 Bulging posterior end of corpus callosum</p> <p>38 Inability to perform a familiar purposeful movement in absence of paralysis</p> <p>39 Cushion-like nucleus of posterior dorsal thalamus</p> <p>41 A hyperkinetic dyskinesia</p> <p>42 Diencephalon's "inner chamber (Gr.)"</p> <p>46 Hook-like part of parahippocampal gyrus</p> |
|--|---|--|---|

**WORD BANK:** Ageusia, agnosia, anosmia, apraxia, aprosody, astrocyte, ataxia, bellspalsy, broca, cajal, caudate, chorea, ciliary, clivus, diploic, dopamine, emissary, folia, fornix, genu, golgi, hindbrain, lambda, lemnisci, leptomennix, mandibular, medulla, neuropil, nystagmus, oligodendrocytes, otic, paleostriatum, pallium, paralysis, pia, preganglionics, ptosis, pulvinar, rotundum, splenium, stroke, subdural, tancytes, tectum, thalamus, uncus, vagus, ventricles, vermis, wernicke.